

ADVANCES IN THE DIAGNOSIS AND MANAGEMENT OF DENTAL CARIES: FROM CONVENTIONAL METHODS TO MINIMALLY INVASIVE DENTISTRY

Shomurodova Zebuniso Tohir qizi
zebunisoshomurodova6@gmail.com

Abstract

Dental caries remains one of the most prevalent chronic diseases worldwide, affecting approximately 2.3 billion individuals. Despite preventive strategies, early detection and optimal management continue to present clinical challenges. Traditional diagnostic methods often identify carious lesions at advanced stages, necessitating invasive restorative interventions. In recent decades, significant technological advances have transformed caries detection and treatment paradigms. Modern diagnostic tools—including digital radiography, laser fluorescence devices, quantitative light-induced fluorescence (QLF), optical coherence tomography (OCT), and artificial intelligence (AI)-based systems—have enhanced early detection accuracy. Simultaneously, treatment strategies have shifted toward minimally invasive dentistry, emphasizing remineralization, bioactive restorative materials, and tissue preservation. This article reviews contemporary diagnostic technologies and therapeutic approaches in dental caries management, highlighting their clinical relevance and future perspectives.

Keywords: dental caries, early diagnosis, minimally invasive dentistry, remineralization, bioactive materials, artificial intelligence

Introduction

Dental caries is a dynamic, biofilm-mediated disease resulting from the interaction between acidogenic bacteria, dietary carbohydrates, and host factors. The process involves progressive demineralization of enamel and dentin, potentially leading to cavitation and pulp involvement if untreated.

Historically, caries management relied on the “drill and fill” approach, focusing on removal of infected tissue followed by restoration. However, this model often resulted in repeated restorative cycles and gradual loss of tooth structure.

Contemporary dentistry emphasizes early detection, risk assessment, prevention, and minimally invasive intervention. The integration of advanced diagnostic technologies and bioactive restorative materials has fundamentally reshaped caries management philosophy.

The aim of this article is to analyze recent advances in caries diagnosis and management and to evaluate their impact on clinical practice.

Materials and Methods

A narrative review of peer-reviewed literature published between 2005 and 2025 was conducted using PubMed, Scopus, and Web of Science databases. Keywords included: *dental caries diagnosis, laser fluorescence, optical coherence tomography, AI in dentistry, and minimally invasive dentistry.*

Inclusion criteria:

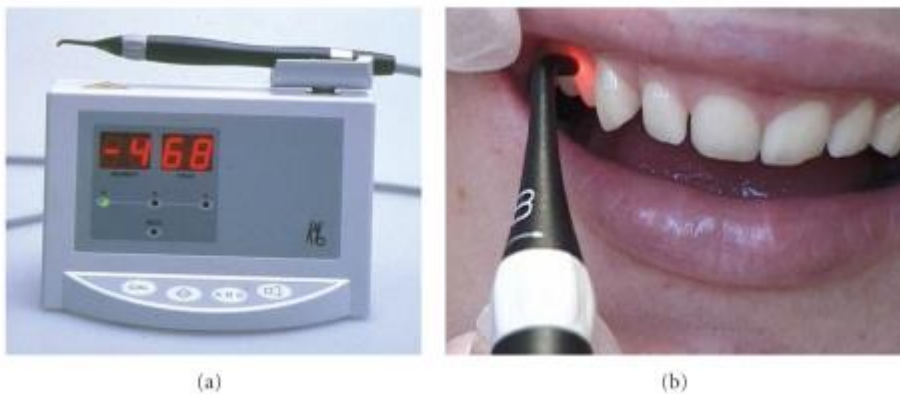- Clinical trials
- Systematic reviews
- Meta-analyses
- In vitro validation studies


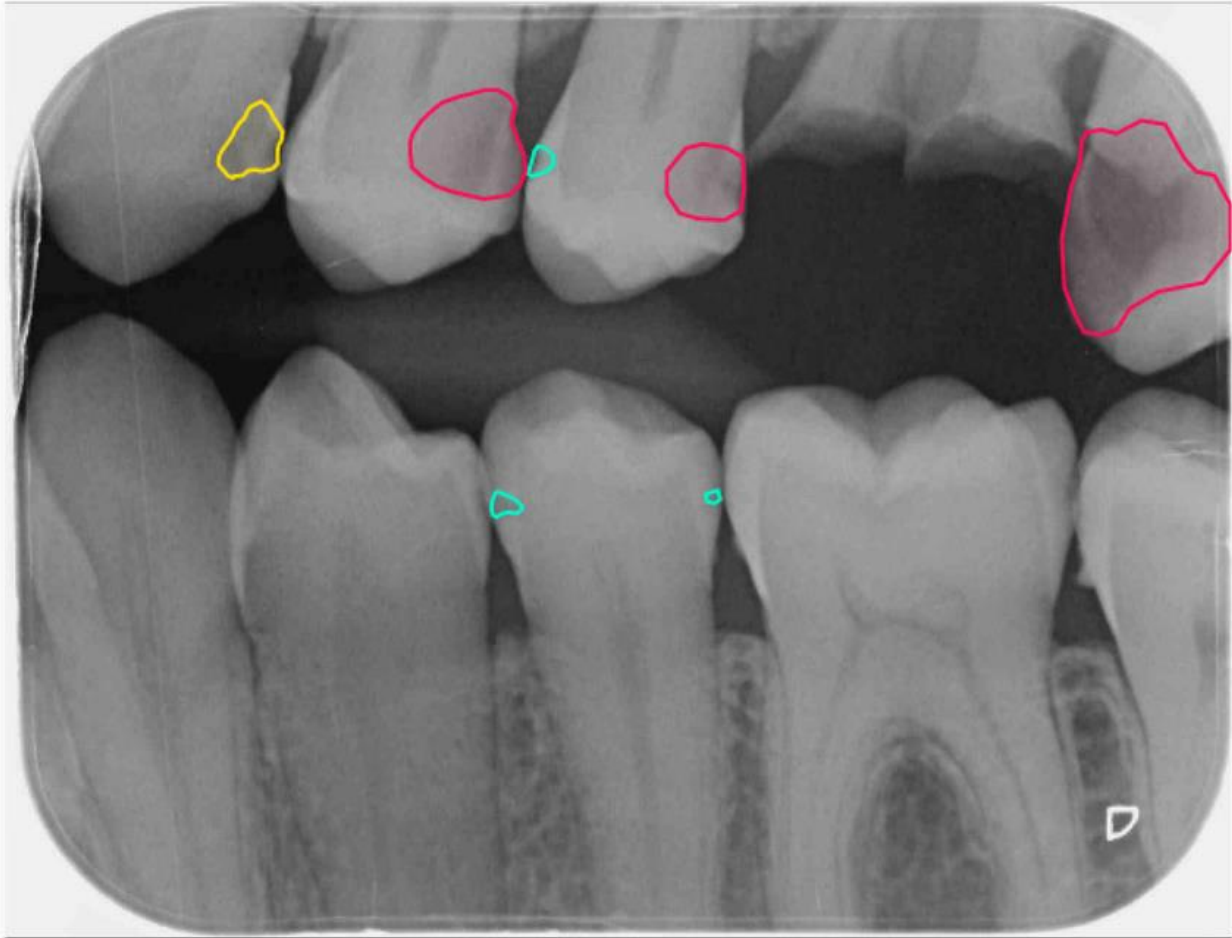
Exclusion criteria:

- Case reports
- Non-peer-reviewed publications

Data were analyzed according to diagnostic accuracy, sensitivity, specificity, clinical applicability, and long-term treatment outcomes.

Modern Diagnostic Technologies





4

Digital Radiography

Digital bitewing radiographs remain a standard diagnostic tool. Compared to conventional film, digital systems offer improved image manipulation, reduced radiation exposure, and enhanced detection of proximal lesions.

Laser Fluorescence Devices

Laser fluorescence technology detects changes in tooth structure based on fluorescence emitted by bacterial metabolites. These devices are particularly useful in identifying occlusal caries at early stages.

Optical Coherence Tomography (OCT)

OCT provides high-resolution cross-sectional images of enamel and dentin. It allows non-invasive visualization of subsurface demineralization and structural integrity.

Artificial Intelligence in Caries Detection

AI-based software analyzes radiographic images to detect subtle lesions that may be missed by human observers. Studies demonstrate improved diagnostic consistency and reduced interobserver variability.

Results

The reviewed studies indicate that modern diagnostic technologies significantly improve early lesion detection compared to visual-tactile examination alone. AI-assisted radiographic analysis demonstrates sensitivity rates exceeding 90% in proximal lesion detection.

Remineralization therapy using fluoride varnishes, calcium-phosphate compounds, and bioactive glass shows high success rates in non-cavitated lesions. Minimally invasive techniques such as selective caries removal preserve pulp vitality and reduce postoperative complications.

Discussion

The paradigm shift toward minimally invasive dentistry is supported by advances in diagnostic accuracy. Early identification of non-cavitated lesions allows implementation of preventive strategies rather than operative intervention.

Bioactive restorative materials contribute to ongoing remineralization and bacterial inhibition. However, implementation challenges include cost, training requirements, and access to advanced technologies.

Future research should focus on long-term clinical validation and integration of AI into routine practice.

Conclusion

Advances in diagnostic technologies and minimally invasive treatment strategies have transformed dental caries management. Emphasis on early detection, prevention, and tissue preservation improves long-term tooth survival and patient outcomes.

References

1. Pitts NB, et al. Dental caries. *Nature Reviews Disease Primers*. 2017.
2. Featherstone JD. The continuum of dental caries. *J Dent Res*. 2004.
3. Schwendicke F, et al. Artificial intelligence in caries detection. *J Dent*. 2020.
4. Gomez J. Detection and diagnosis of dental caries. *J Dent Clin North Am*. 2013.
5. Banerjee A. Minimal intervention dentistry. *Br Dent J*. 2013.
6. Young DA, et al. Caries management by risk assessment. *J Calif Dent Assoc*. 2007.
7. Alammari MR. Optical coherence tomography in dentistry. *Saudi Dent J*. 2019.
8. Walsh LJ. Fluorescence devices in caries detection. *Aust Dent J*. 2008.